

# Latin Comparative Pathology Group

## The Latin Subdivision of the CL Davis Foundation

### Diagnostic Exercise

Case #: 9 Month: May Year: 2011

**Contributor:**

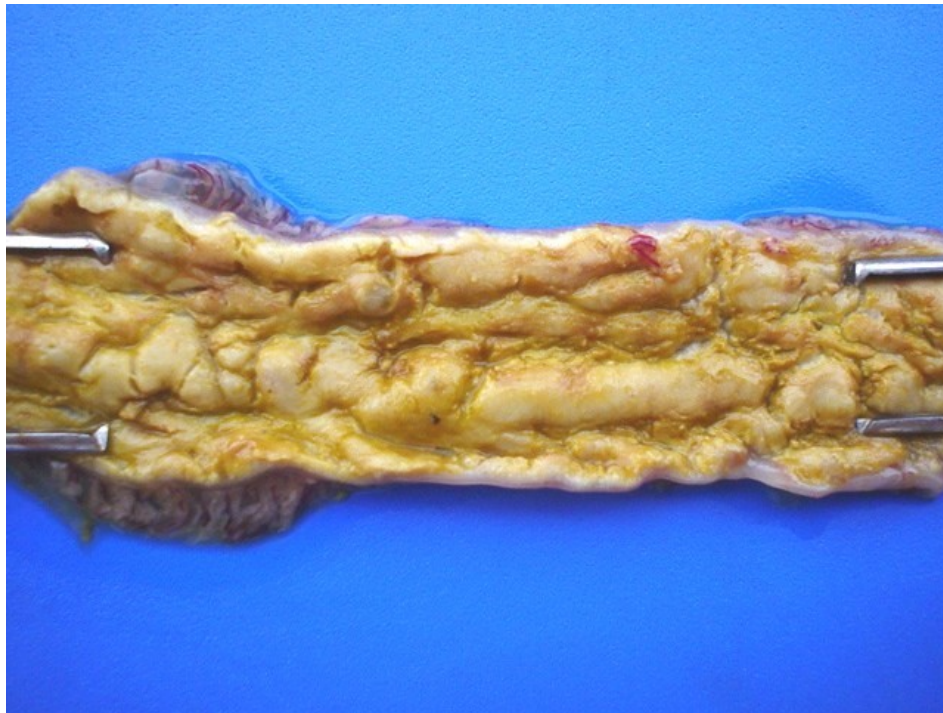
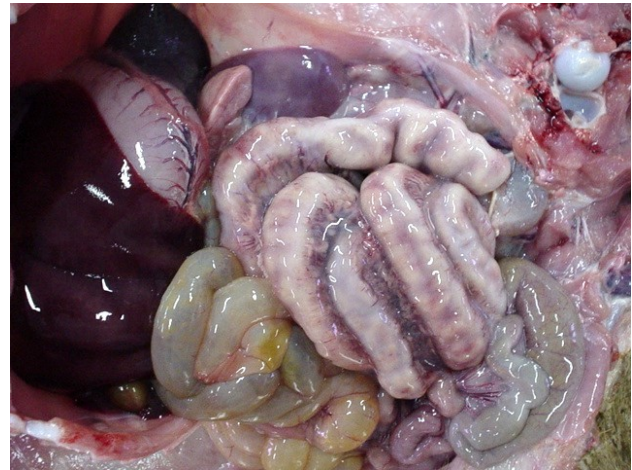
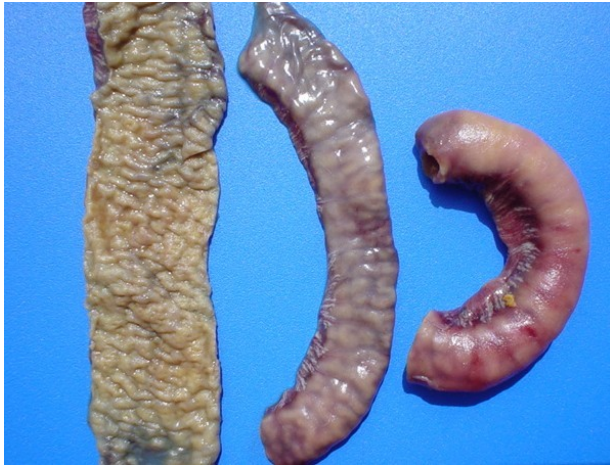Roselene Ecco, DVM, MSc, PhD - Universidade Federal de Minas Gerais (UFMG) - Brazil

**Clinical History:** Five wild pigs died and were necropsied between August and December 2002. Four of the five animals showed lesions in the large intestine and all five showed lesions in the small intestine. The deaths started following the introduction of five wild boards from another farm, where they had been used for breeding. Higher mortality rates were observed after weaning (weaning age 50 to 55 days) in pigs between 50 and 90 days of age; however, five affected animals were much younger (30 days old). The clinical signs were characterized by reduced growth rate, inappetance, greyish diarrhea and fever (approximately 104°F).

**Laboratory Findings:** PCR, IHC and bacteriological culture were performed.

**Necropsy Findings:** Most of lesions in the large intestine were observed in the cecum and spiral colon. Affected animals had linear, circular or even diffuse areas of necrotic mucosa with yellowish, friable material forming a diphtheric membrane firmly adhered to the intestinal mucosa. Similar lesions were observed in the small intestine.

**Gross and/or microscopic image:**



**Follow-up questions:** *Description, Morphologic diagnosis, Differential diagnosis, Cause, Etiologic diagnosis, Etiology, Immuno/Histochemical and PCR findings.*

Please send your comments/questions to the whole LCPG list by hitting "reply to all".

A final document containing this material with answers and a brief discussion will be posted on the C. L. Davis website by the end of the current month ([http://www.cldavis.org/lcpg\\_english.html](http://www.cldavis.org/lcpg_english.html)).