

Latin Comparative Pathology Group

The Latin Subdivision of the CL Davis Foundation

Diagnostic Exercise

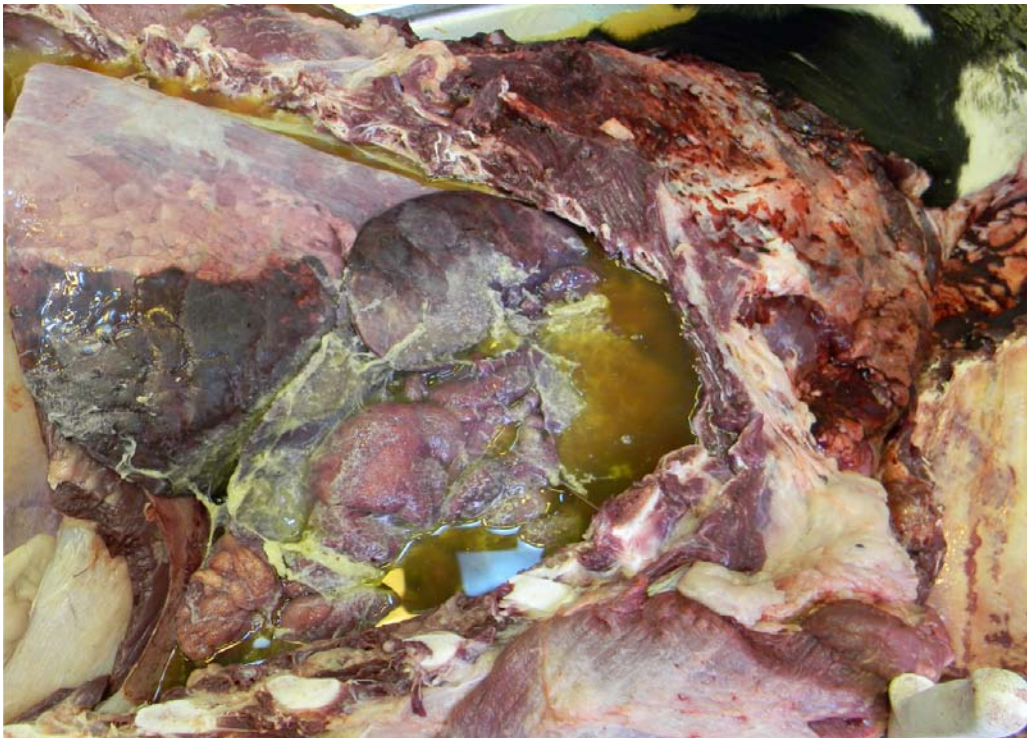
Case #: 8 Month: April Year: 2011

Contributor: Fábio Brum Rosa, DVM; Universidade Federal de Santa Maria, RS - Brazil

Clinical History: 13 months old, female Holstein calf with dyspnea, foaming at the mouth and nasal discharge for two days.

Necropsy Findings: The oral mucosa was slightly cyanotic. There was bilateral mucopurulent and bleeding nasal discharge and striking gross changes in the thoracic cavity (see image below).

Gross and/or microscopic image:



Follow-up questions: Morphologic diagnosis, two possible causes.

Please send your comments/questions to the whole LCPG list by hitting "reply to all".

A final document containing this material with answers and a brief discussion will be posted on the C. L. Davis website by the end of the current month (http://www.cldavis.org/lcpg_english.html).