



# Latin Comparative Pathology Group

## The Latin Subdivision of the CL Davis Foundation

### Diagnostic Exercise

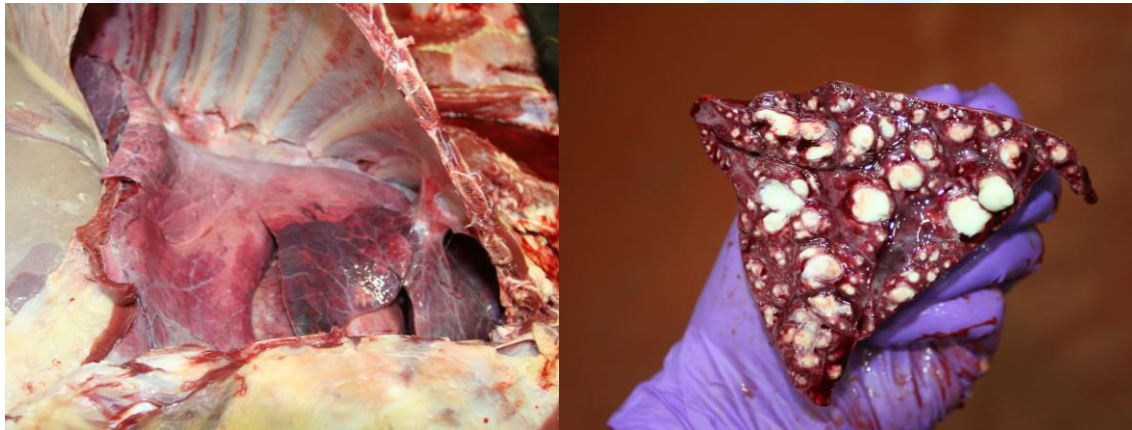Case #: 62 Month: November Year: 2015

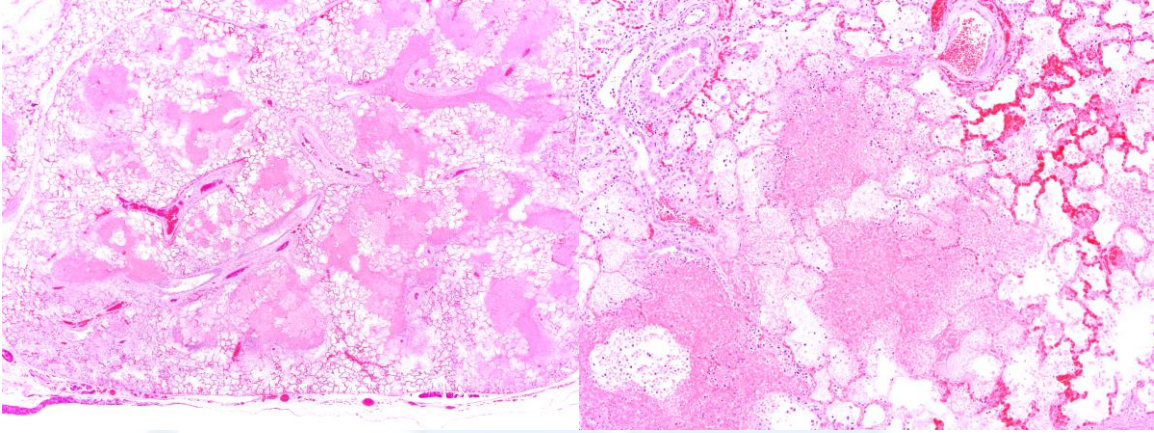
**Contributor:** Santiago Diab, DVM, Dip ACVP. Assistant Professor, University of California, Davis. California Animal Health and Food Safety Laboratory system.

**Clinical History:** One year old Angus heifer presented with a history of poor appetite, coughing, runny nose, dehydration, and wobbly steps.

**Necropsy Findings:** The right middle lung lobe was focally adhered to the thoracic wall by a band of connective tissue. There was moderate, cranioventral, well-demarcated, bilateral pulmonary consolidation. Small- to mid-size airways were ectatic (bronchiectasis) and filled with abundant tan to yellow, caseous exudate. The total area of lung affected by these alterations was approximately 20%.

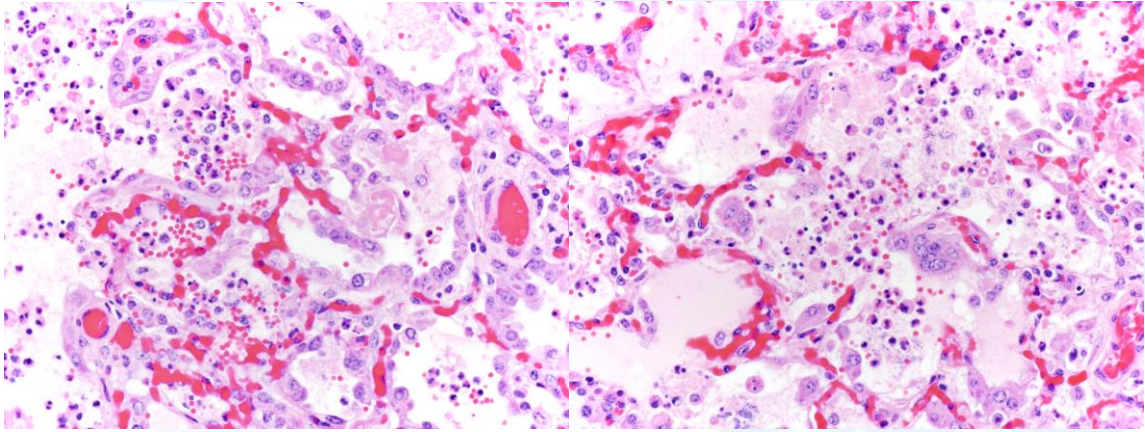
**Gross and/or microscopic image:**





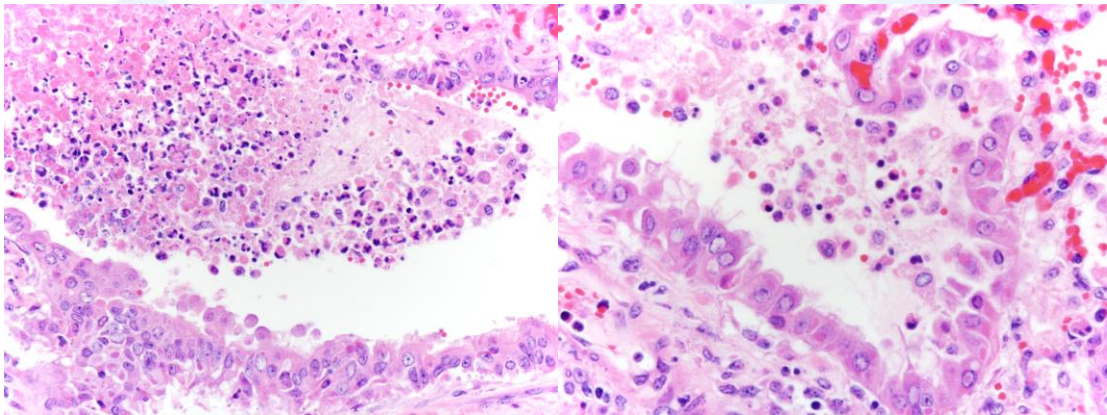
HE, 2x.

HE, 4x.



HE, 40X

HE, 40X



HE, 40X

HE, 60X

**Follow-up questions:** Morphologic diagnosis, differential diagnosis, typical gross and microscopic findings,

Please send your comments/questions to the whole LCPG list by hitting "reply to all".

A final document containing this material with answers and a brief discussion will be posted on the C. L. Davis website by the end of the current month ([http://www.cldavis.org/lcpg\\_english.html](http://www.cldavis.org/lcpg_english.html)).

G  
P  
D  
C  
L

