



Latin Comparative Pathology Group

The Latin Subdivision of the CL Davis Foundation

Diagnostic Exercise

Case #: 37 Month: October Year: 2013

Contributor:

Jana M. Ritter, DVM, DACVP, Dalen Agnew, DVM, PhD, DACVP; Diagnostic Center for Population and Animal Health and Department of Pathobiology and Diagnostic Investigation, Michigan State University

Clinical History: 7 week old Netherland Dwarf rabbit from a breeder who experienced numerous animal deaths within 5-7 days after shipping to a distributor.

Laboratory Findings: N/A

Necropsy Findings: Both renal cortical surfaces contained numerous 1-2mm diameter superficial depressions.

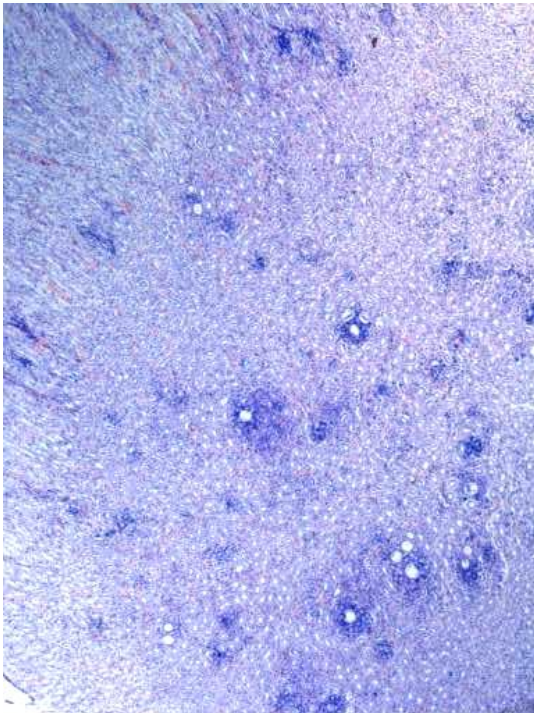
Microscopic findings: please see the next page.

Follow-up questions: Microscopic Description, morphologic diagnosis, etiology, and lesions in other organs.

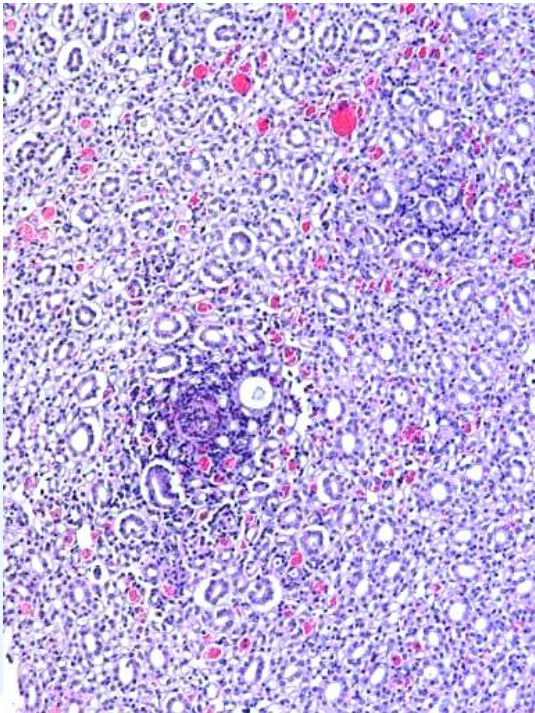
Please send your comments/questions to the whole LCPG list by hitting "reply to all".

A final document containing this material with answers and a brief discussion will be posted on the C. L. Davis website by the end of the current month (http://www.cldavis.org/lcpg_english.html).

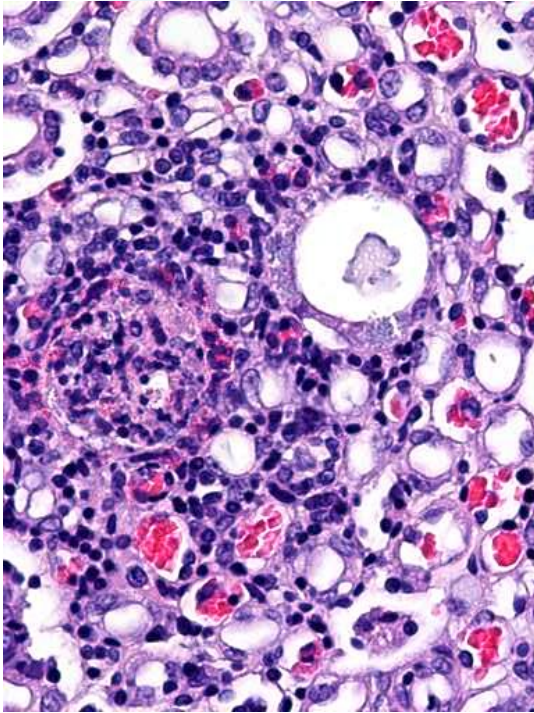
Microscopic images: Kidney



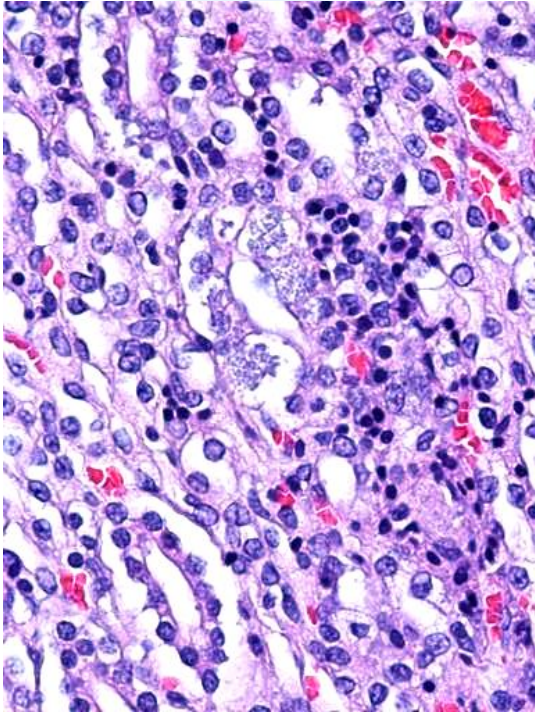
Giemsa, 2.5X



H&E, 10X



H&E, 40X



H&E, 40X