



Latin Comparative Pathology Group

The Latin Subdivision of the CL Davis Foundation

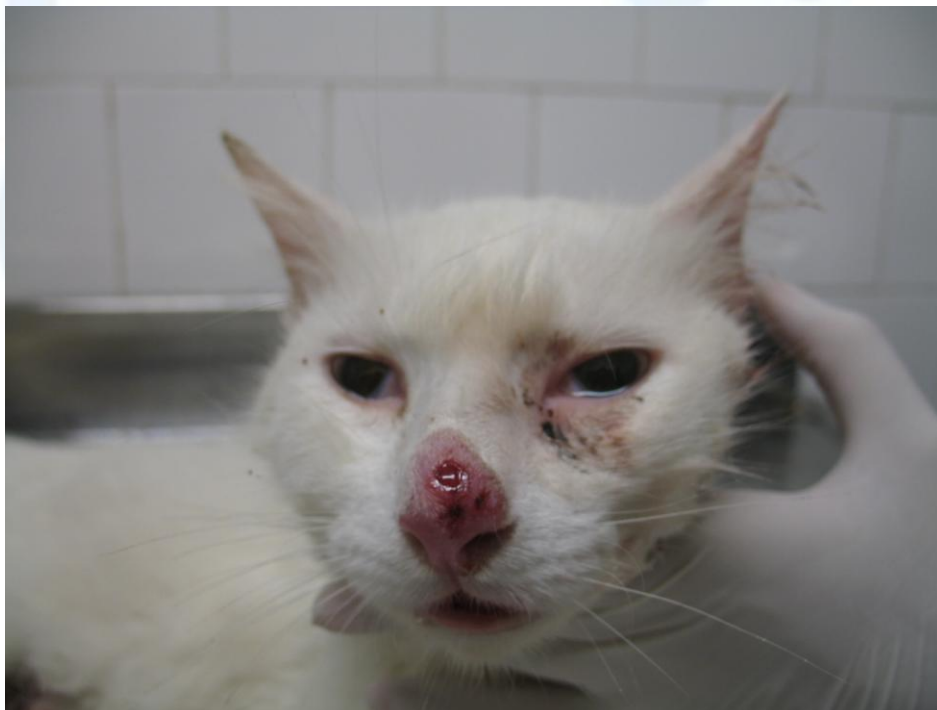Diagnostic Exercise

Case #: 20 Month: April Year: 2012

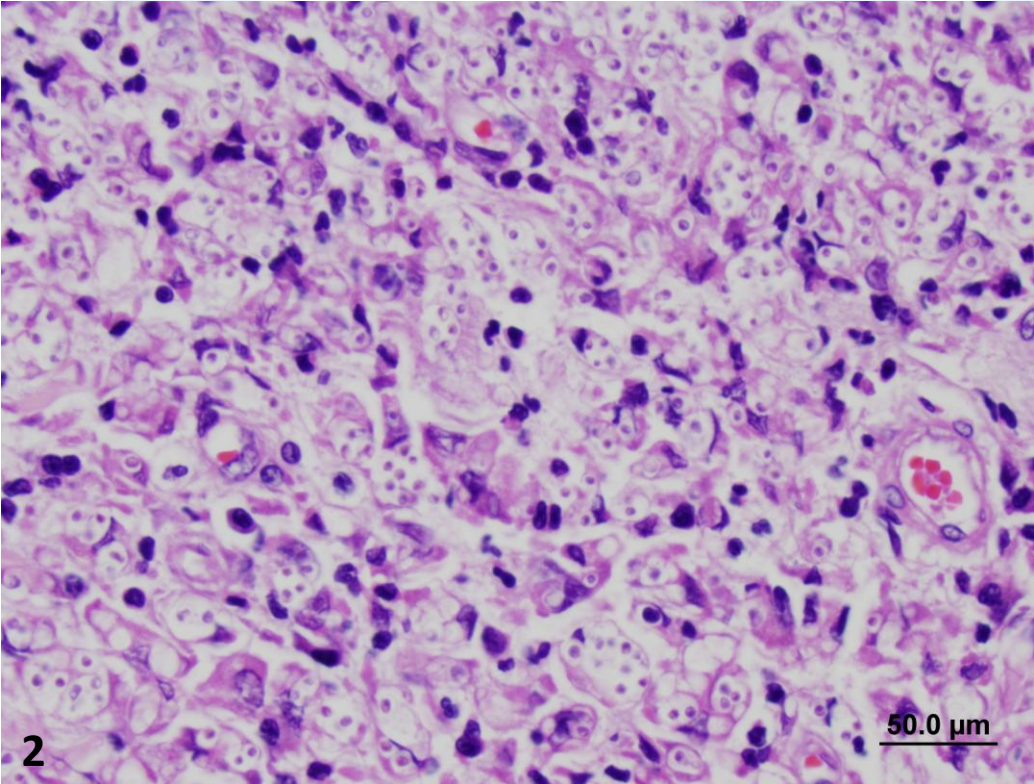
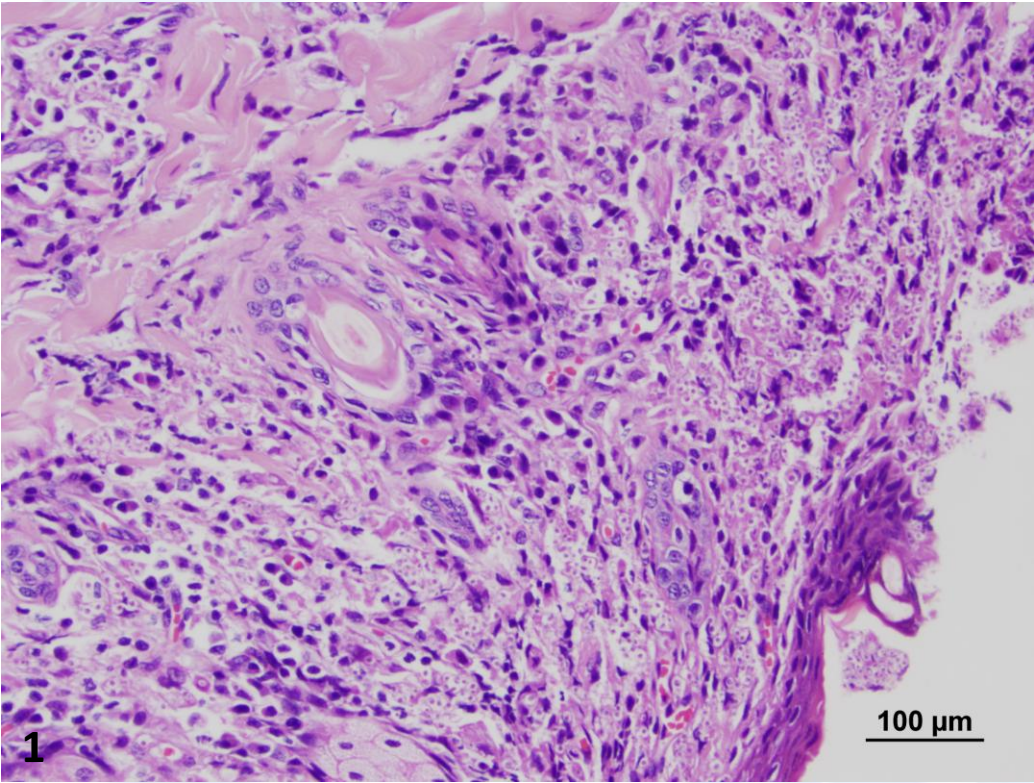
Contributor: Dr. Rodrigo Caldas Menezes, DVM, PhD and Dr. Luisa Helena Monteiro de Miranda, DVM, MSc, Evandro Chagas Clinical Research Institute, Oswaldo Cruz Foundation, Rio de Janeiro, RJ, Brazil.

Clinical History: A three-year-old, male, castrated, domestic shorthair cat, weighing 3.2 kg, presented with multiple cutaneous lesions. This animal also had frequent sneezing, partial bilateral obstruction of nostrils due to severe edema of nasal mucosa, dyspnea, enlargement of the left mandibular lymph node and emaciation. In addition, the cat was in poor body condition and dehydrated. Euthanasia was performed due to poor prognosis.

Necropsy Findings: Please see gross image.



Microscopic images: HE, 20x (Figure 1) and 40x (Figure 2).



Follow-up questions:

1. Morphologic diagnosis.
2. Etiologic diagnosis.
3. Differential diagnosis.

Please send your comments/questions to the whole LCPG list by hitting "reply to all".

A final document containing this material with answers and a brief discussion will be posted on the C. L. Davis website by the end of the current month (http://www.cldavis.org/lcpg_english.html).