



# Latin Comparative Pathology Group

## The Latin Subdivision of the CL Davis Foundation

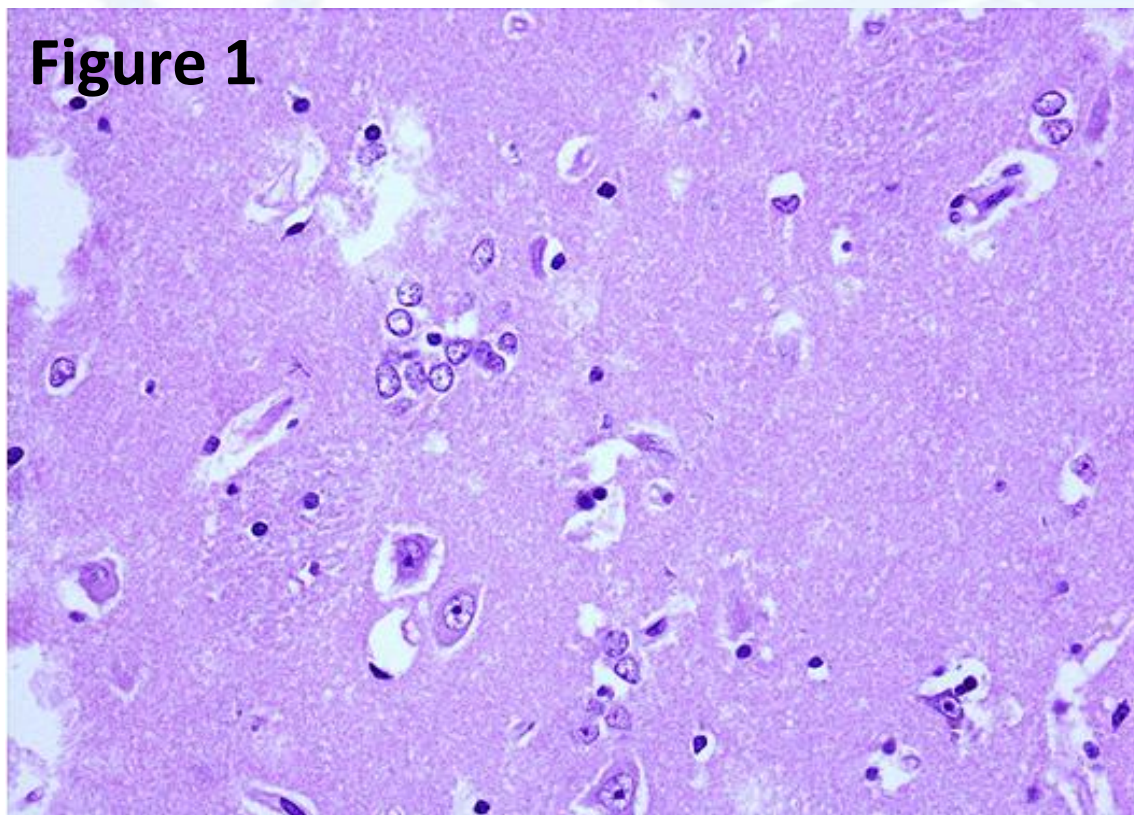
### Diagnostic Exercise

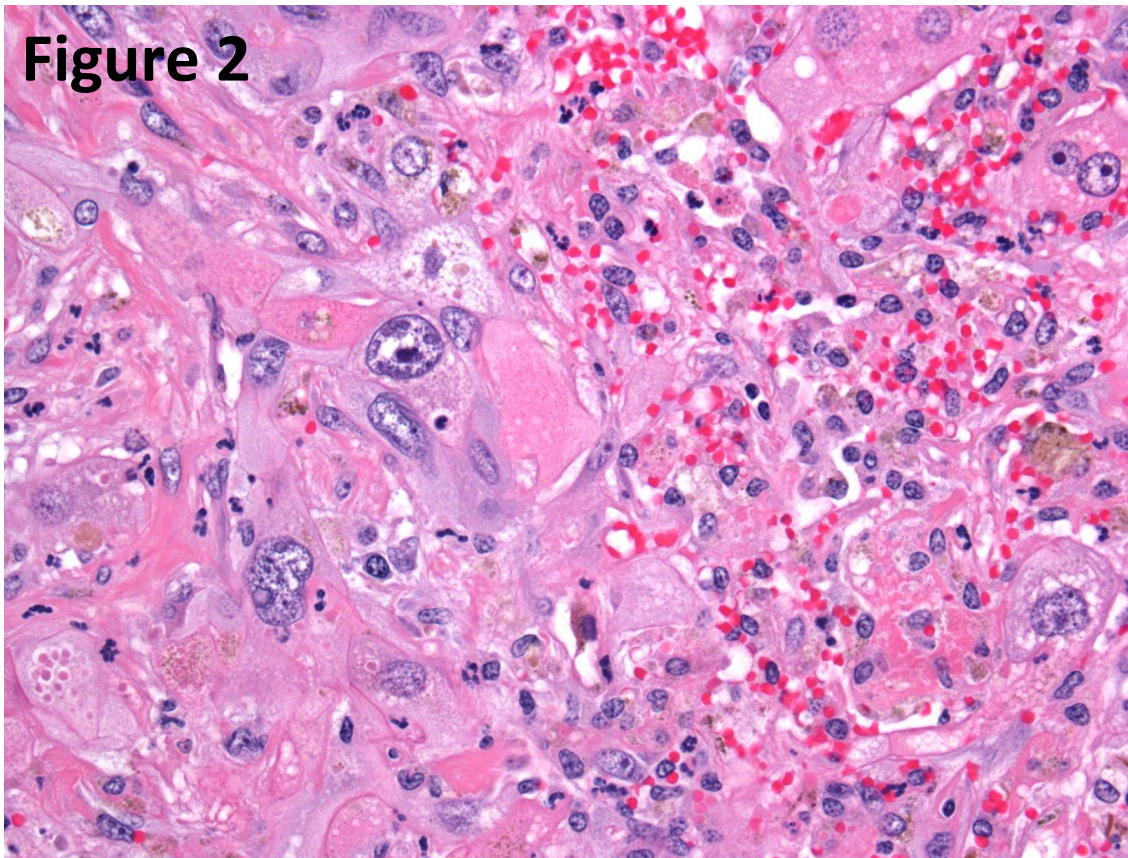
Case #: 17 Month: January Year: 2012

**Contributor:** Francisco Uzal, California Animal Health and Food Safety Laboratory System; San Bernardino Branch, University of California - Davis

**Clinical History:** 25 year old Quarter Horse gelding with a history of poor nutritional condition and circling aimlessly for the past 3 days. On post-mortem examination there was serous atrophy of the peri-renal and pericardial fat and mild but generalized muscle atrophy. The liver was approximately 30% smaller than normal, but otherwise unremarkable. No other significant gross abnormalities were observed.

**Gross and/or microscopic image:** HE, 20X and 40X respectively.





**Follow-up questions:**

1. Histopathologic description (figures 1 and 2)
2. *Morphologic diagnosis* (figures 1 and 2)
3. *Pathogenesis*
4. *Possible etiology*

Please send your comments/questions to the whole LCPG list by hitting "reply to all".

A final document containing this material with answers and a brief discussion will be posted on the C. L. Davis website by the end of the current month ([http://www.cldavis.org/lcpg\\_english.html](http://www.cldavis.org/lcpg_english.html)).