



Diagnostic Exercise

From The Davis-Thompson Foundation*

Case #: 114 Month: February Year: 2019

Contributors: Tamires Goneli Wichert Teodoro,^{1,2,3} DVM; Tatiane Terumi Negrão Watanabe,^{2,3} DVM, MS, PhD; Cole Sandow,² DVM; Ann Chapman,² DVM, MS, DACVIM-LAIM; Colin Mitchell,² BVMS, MS, DACVS; Frank Andrews,² DVM, MS, DACVIM-LAIM; Renee Carter,² DVM, DACVO; Nobuko Wakamatsu,^{2,3} DVM, PhD, DACVP, DACPV. ¹Universidade Federal de Lavras, Lavras, MG, Brazil; ²Louisiana State University, School of Veterinary Medicine, Baton Rouge, LA, USA; ³Louisiana Animal Disease Diagnostic Laboratory, Baton Rouge, LA, USA.

Clinical History: A 16.5-year-old Warmblood gelding presented with a painful and non-visual right eye. The eye was enucleated and submitted for histologic evaluation.

Microscopic Image(s):

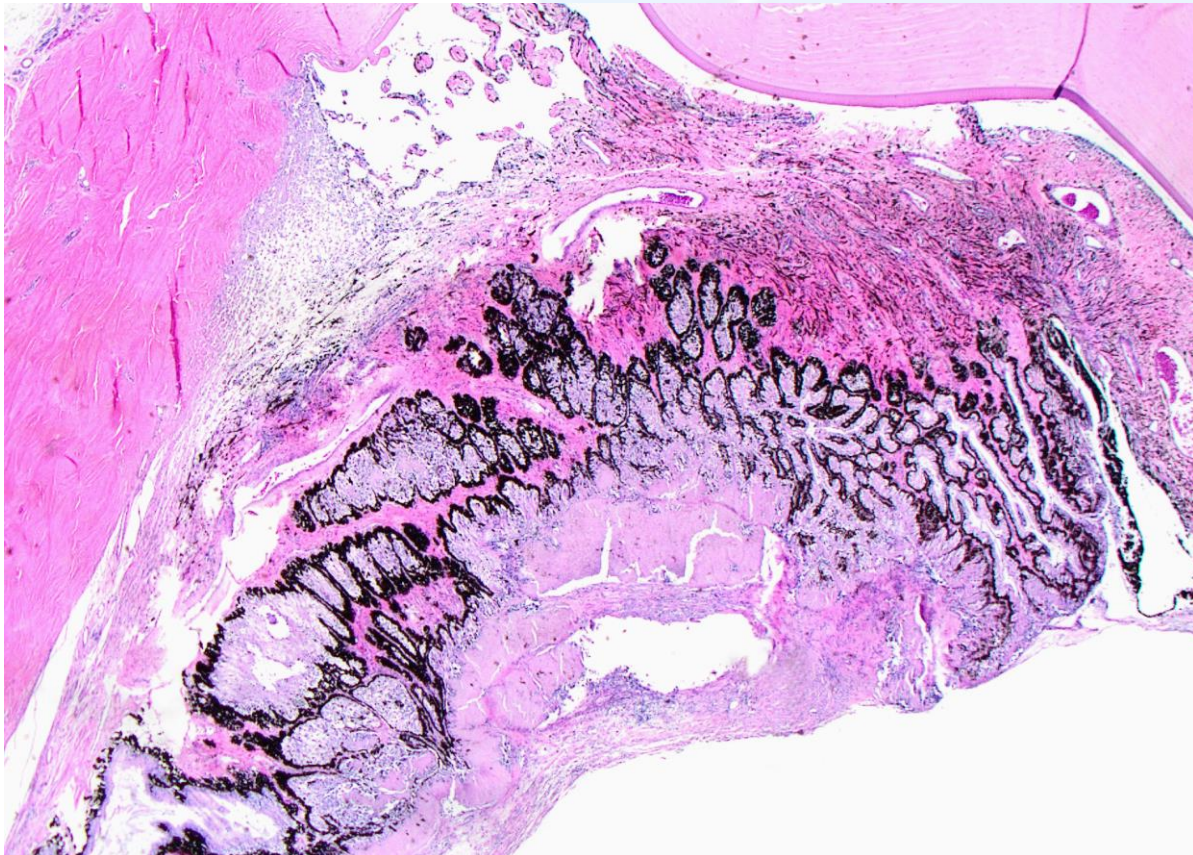


Figure 1. Warmblood horse right eye, Hematoxylin and Eosin, 2x objective.

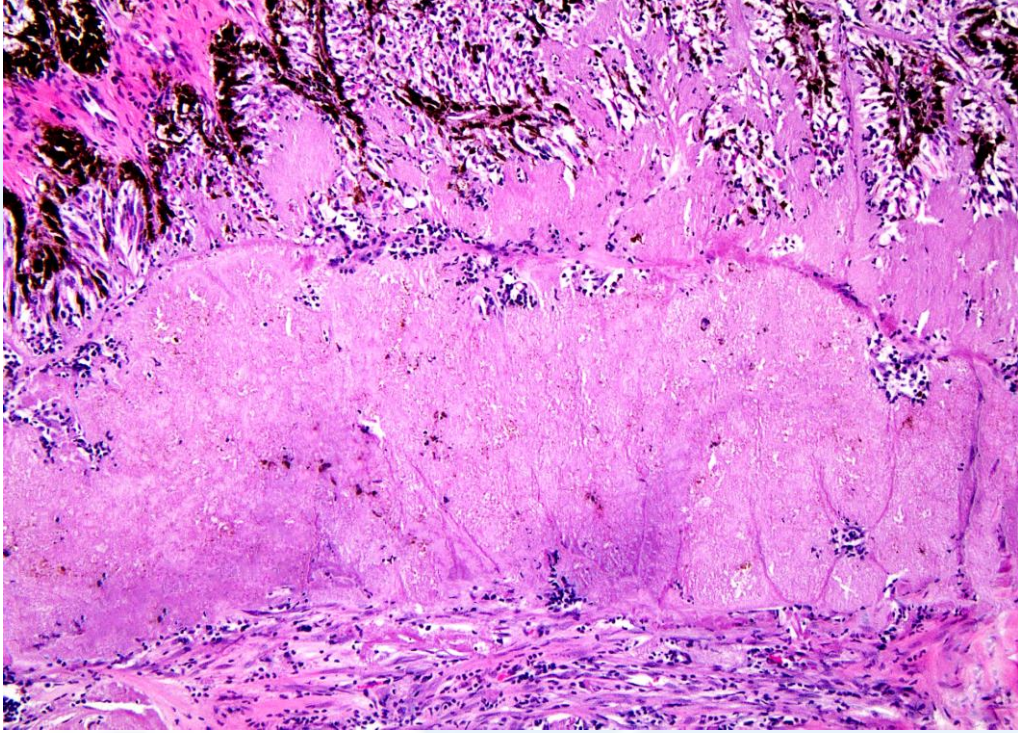


Figure 2. Warmblood horse right eye, Hematoxylin and Eosin, 10x objective.




Figure 3. Warmblood horse right eye, Congo Red Polarized, 20x objective.

Follow-up Questions: Microscopic description; Condition; Ancillary testing.

*The Diagnostic Exercises are an initiative of the **Latin Comparative Pathology Group (LCPG)**, the Latin American subdivision of The Davis-Thompson Foundation. These exercises are contributed by members and non-members from any country of residence. Consider submitting an exercise! A final document containing this material with answers and a brief discussion will be posted on the CL Davis website (http://www.cldavis.org/diagnostic_exercises.html).

Associate Editor for this Diagnostic Exercise: Ingeborg Langohr

Editor-in-Chief: Vinicius Carreira